

FORSCAR Patented New Scar Technology (NST)

FORSCAR NST forms a non-tacky, substantive, semioclusive barrier to treat old and new scars included Hypertrophic and Keloid scars.

Its flexible film-forming technology treats scars even on irregular areas such as the hands and elbows, which are normally difficult to cover.

ACTION 1

Increases hydration of stratum corneum and thereby facilitates regulation of fibroblast production and reduction in collagen production. It results into softer and flatter scar.

Protects the scarred tissue from bacterial invasion and prevents bacteria-induced excessive collagen production in the scar tissue. Modulates the expression of growth factors.

ACTION 2

Its unique antioxidant property (5% Squalane) contributes to the process of wound healing by reducing ROS (Reactive Oxygen Species) levels which act as free radicals and delay wound healing. It has been proven by in vitro studies that Squalane reduces ROS levels and protects against oxidative DNA damage.*

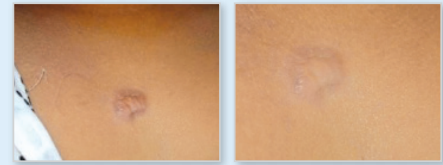
RESULT: In response to the oxidative stress occurring at the wound site, antioxidant Squalane quench free radicals and reestablish the necessary environment for normal scar development.

* Warleta F, Campos M. Allouche Y, Sanchez-Quesada C, Ruiz-Mora J, Beltrán G, et al. Squalane protects against oxidative DNA damage in MCF10A human mammary epithelial cells. *Food Chem Toxicol* 2010;48(4):1092-100.

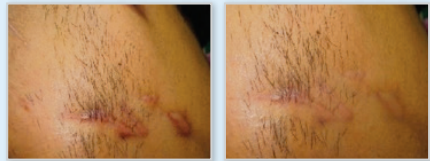
References

- > Bologna JL, Jorizzo JL, Rapini RP, et al., editors. *Dermatology*. 2nd edition. Spain: Mosby Elsevier; 2008.
- > Bayat A, Arscott G, Ollier WE, McGrouther DA, Ferguson MW. Keloid disease: clinical relevance of single versus multiple site scars. *The British Association of Plastic Surgeons*. 2005;58:28-37.
- > Chernoff WG, Cramer H, Su-Huang S. The efficacy of topical silicone gel elastomers in the treatment of hypertrophic scars, keloid scars, and post-laser exfoliation erythema. *Aesthet Plast Surg*. 2007;31:495-500.
- > Butler P, Ly D, Longaker M, et al. Use of organotypic coculture to study keloid biology. *Am J Surg*. 2008;195:144.
- > Varga J, Pasche B. Transforming growth factor, as a therapeutic target in systemic sclerosis. *B Nat Rev Rheumatol*. 2009;5:200-206.
- > Cutroneo KR, White SL, Phan SH, Ehrlich HP. Therapies for bleomycin induced lung fibrosis through regulation of TGF-beta1 induced collagen gene expression. *J Cell Physiol*. 2007;211:585-589.
- > Durani P, Bayat A. Levels of evidence for the treatment of keloid disease. *J Plast Reconstr Aesthet Surg*. 2008;61(1):4-17.
- > Mustoe T, Cooter R, Gold MH, et al. International clinical recommendations on scar management. *Plast Reconstr Surg*. 2002;110:560-571.
- > Davison SP, Sobanko JE, Clemens MW. Use of a Collagen glyco-saminoglycan copolymer (Integra) in combination with adjuvant treatments for reconstruction of severe chest keloids. *J Drugs Dermatol*. 2010;9(5):542-548.
- > Reish R, Eriksson E. Scars: a review of emerging and currently available therapies. *Plast Reconstr Surg*. 2008;122:1068.
- > Butler P, Longaker M, Yang G. Current progress in keloid research and treatment. *J Am Coll Surg*. 2008;206:731.
- > McGrath M. Topical scar modification: help or hype? *Aesthet Surg J*. 2005;25:304-306.

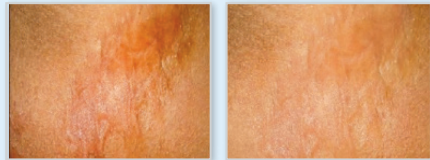
The Efficacy of Silicone Gel for the Treatment of Hypertrophic Scars and Keloids



A patient with minor keloid before and after treatment*



A patient with hypertrophic scar before and after treatment*



A patient with burn scar before and after treatment*

Table1 Grading of scars before treatment

Grading	Percentage
I (Normal)	0,07
II (Mildly hypertrophic)	26,6
III (Hypertrophic)	50
IV (Keloid)	23,33

At the beginning, the commonest type of scars were hypertrophic scars (Grade III, 50%) followed by mildly hypertrophic scars (Grade II, 26.6%) and keloids (Grade IV, 23.33%).

Table2 Grading of scars after treatment

Grading	Percentage
I (Normal)	60
II (Mildly hypertrophic)	20
III (Hypertrophic)	10
IV (Keloid)	10

After treatment, improvement was noted in the scars. 60% scars were graded as normal (Grade I), while 20% were graded as mildly hypertrophic (Grade II). 10% of scars were of Grade III and IV at the end of study; 10% in each grade [Table 2].

* Neerja Puri and Ashutosh Talwar. The Efficacy of Silicone Gel for the Treatment of Hypertrophic Scars and Keloids. *J Cutan Aesthet Surg*. 2009 Jul-Dec; 2(2): 104-106

UNIQUE SILICONE BLEND WITH 5% SQUALANE

Benefits and Product Features

- Softens, flattens and fades old and new scars included Hypertrophic and Kleoid scars.
- Prevents formation of abnormal scars.
- Ensures constant contact time to the entire skin surface to work 24 hours.
- Compatible with human biology, tested according to ISO 10993.
- Suitable for sensitive skin.
- Relieves itching and discomfort.
- Indicated for use of children.
- Self-dry, invisible, breathable sheet.

FORSCAR NST has many outstanding advantages over traditional silicone gels and silicone sheets.

Its unique patented silicone composition provides

IMPROVED

- Substantivity,
 - Occlusivity,
 - Lubricity and
 - Detackification
- which are qualities often lack in scar therapies.



Additionally, its unique antioxidant property (5% Squalane) contributes to the process of wound healing.

FORSCAR NST is unique patented technology composed of;

1
Silicone
Gum

2
Silicone
Fluid

3
Silicone
Wax

4
Silicone
Volatiles

5
5%Anti-oxidant
Olive Oil
Squalane



SCAR RECOVERY GEL
10-20 ml

SCAR RECOVERY GEL
UV SPF 30 20 ml

SCAR RECOVERY
SPRAY 100 ml